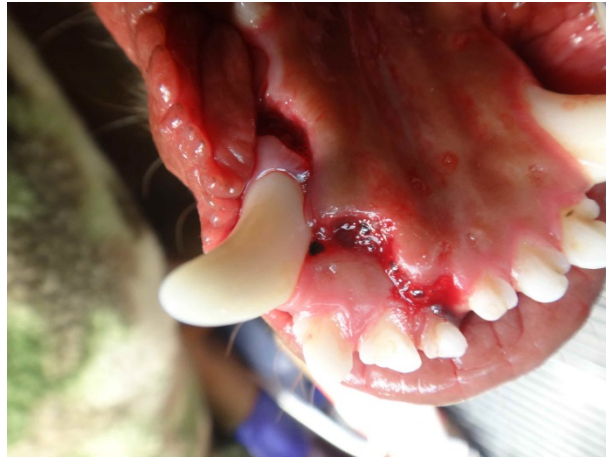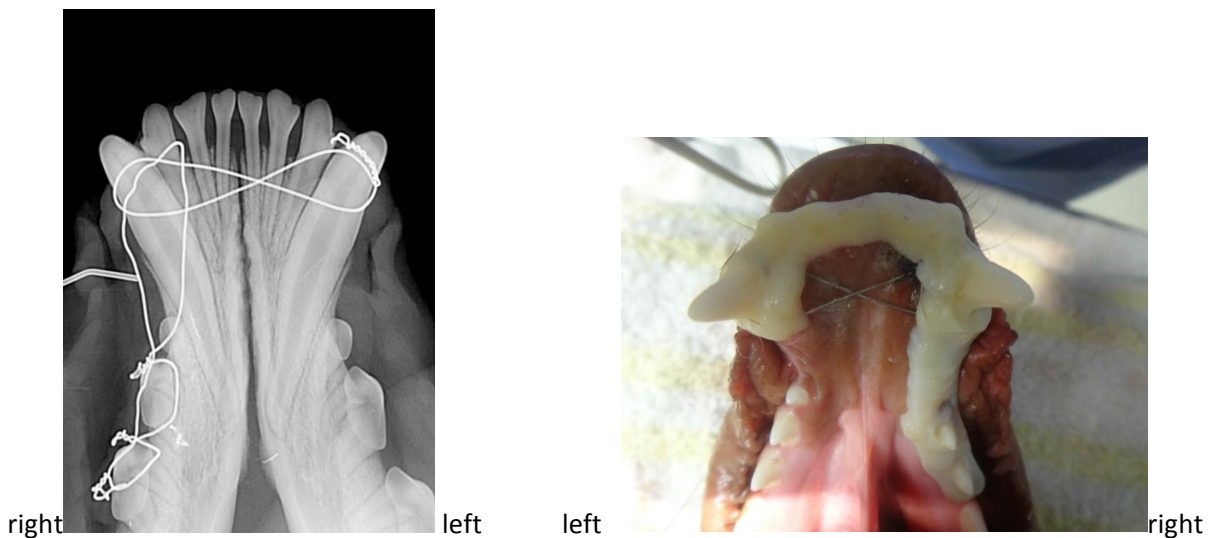


May Dental E-Newsletter (Jaw Fracture Repair)

Veterinary dentistry involves so much more than treating the teeth. The entire oral cavity is our domain and we are frequently presented with patients that have oral fractures requiring repair. We are able to accomplish this by incorporating dental radiographs to assess the bone and the teeth. The ultimate result is a patient with a stable and comfortable bite. This young Labrador Retriever presented to us after falling on the stairs and fracturing his symphysis and right mandible distal to the canine tooth.



By placing the wire strategically to avoid harming the teeth, it was possible to stabilize the fracture sites. After the lacerations were sutured, a product called Protemp Garant was placed over the wire and teeth to provide greater stability. This will remain in place for approximately 8 weeks after which the patient will be anesthetized for removal and final dental radiographs.



The other note I would like to include: (please do not include this on the website)

We are excited to announce final installation of an oxygen generator and decicated oxygen cages in our practice! Pre-oxygenation of patients is now part of our standard anesthetic protocol.



A reminder for the newsletter:

Is your staff as efficient with dental radiographs as you would like? Are full mouth radiographs standard for all of your dental procedures? If not, please enroll in our Digital Dental Radiography class on Wednesday, June 18.