

JANUARY DENTAL E-NEWSLETTER

Fractured teeth. What veterinarian can get through a week of small animal practice without seeing at least one fractured tooth? There are sometimes misperceptions as we speak with referring veterinarians about the treatment options.

Misperception #1: You can't do a root canal on an abscessed tooth

We can indeed! If the files go straight through the apex of the tooth, or if there is a root fracture then that would change the plan. However, the overwhelming majority of abscessed teeth can be saved with a root canal IF there is not significant periodontal disease.

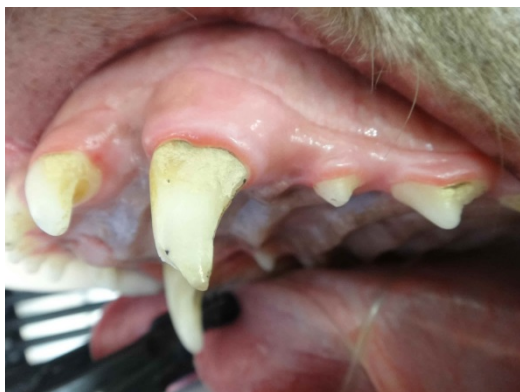Misperception #2: You can put a crown over a tooth with a fracture and pulp exposure

If there is pulp exposure the only two options are extraction or root canal. A crown can be used to further protect a tooth that has had a root canal.

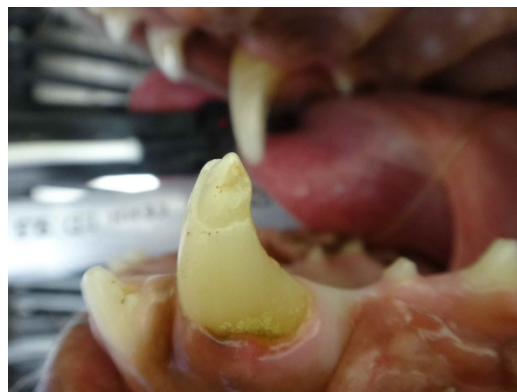
Misperception #3: When CAN I refer for a crown ONLY?

If there is a fracture WITHOUT pulp exposure and no evidence of periapical abscess, significant periodontal disease and the fracture is not significant beneath the gingival margin, then a crown is an option.

This is a patient that was referred due to fractured teeth – what are the treatment options?
What is your first diagnostic step?



Hint: there is pulp exposure evident on the palatal aspect of this tooth



Hint: There is no pulp exposure evident even once anesthetized

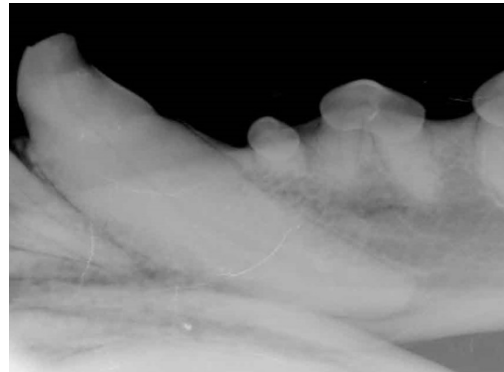
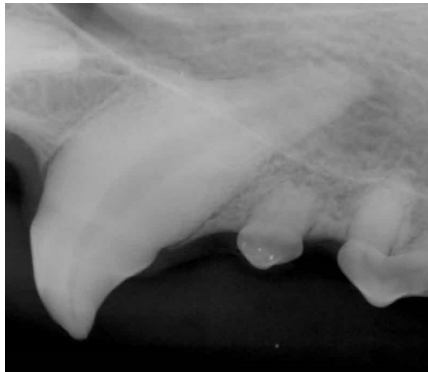BREAK HERE TO THE WEBSITE LINK

If you said dental radiographs are the next step, you are correct! (That seems to be a common answer isn't it? Sorry folks, but without dental radiography there is just no guessing on cases like this)

Do you see any abnormalities? Any differences in one canine tooth vs. the other?

Take a look at the canal sizes – they should be symmetrical. Can you appreciate the maxillary canine tooth has a wider pulp canal? This indicates pulp death, necessitating either extraction or root canal.

Now look at the apex of both teeth – see the periapical lucency involving the maxillary canine tooth? This is another indication of endodontic disease and pulp death. The mandibular canine tooth, on the other hand, appears radiographically normal.



These are the facts:

Maxillary canine tooth:

*Fracture with pulp exposure

*Periapical lucency

*Wide pulp canal

Mandibular canine tooth:

*Fracture without pulp exposure

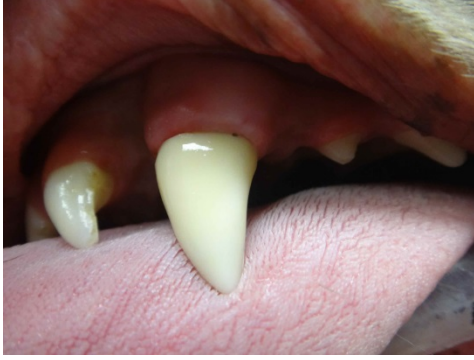*No radiographic abnormalities

TREATMENT OPTIONS?

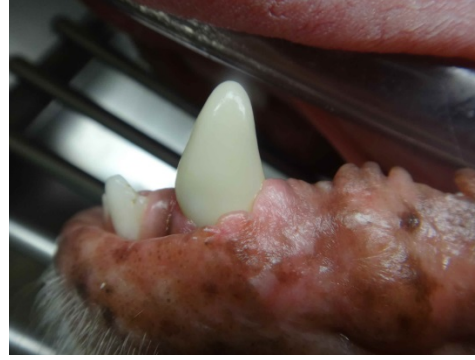Root canal or extraction

No root canal or extraction needed

IS A CROWN AN OPTION?



YES!



YES!

Misconception #4: A tooth colored crown is less durable

Tooth colored crowns have traditionally been made of porcelain and were more likely to chip. In recent years, they are actually carved from a solid block of zirconium and are extremely durable. The silver crowns we have fabricated out of titanium, which is equally as durable.