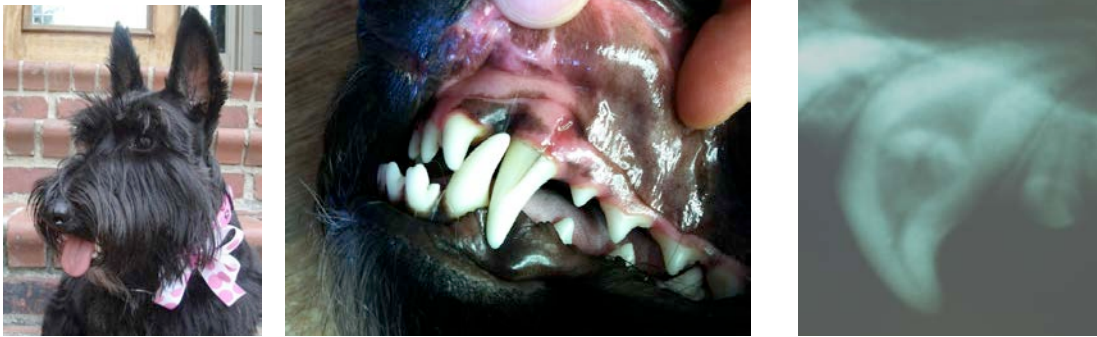

Case of the Month:

By: Heather L. Duncan, DVM; Practice Limited to Veterinary Dentistry & Oral Surgery

Bonnie is a 1 year old, FS, Scottish Terrier, who was presented with a 2 day history of pawing at the left side of her mouth and rubbing the left side of her face on the floor. There was a vertical “crack” or lesion on the left maxillary canine tooth (204), coronal (toward the crown) from the attached gingiva.

Clinical pictures and radiograph of Bonnie & her left maxillary canine tooth (204):



What is your next step for Diagnostics or Treatment?

Anesthesia with dental radiographs was the next diagnostic step. Upon clinical evaluation of 204: a vertical fracture is visible in the majority of the crown and continues below the gumline. There is a fistulous tract that is present associated with the attached gingiva of 204. There is a circular radiodense material present in center of this tooth on the x-ray. There also is a wide blunderbuss pulp chamber mid-tooth that is not consistent with the diameter of the pulp chamber present at the cusp tip or the apex.

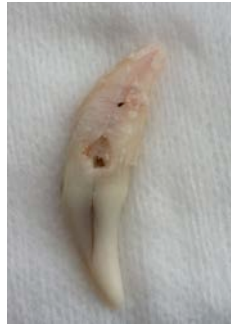Based on the clinical and radiographic findings, this tooth appears to be non-vital.

What is the best treatment option for this pet?

Normally, when important functioning teeth in dogs (Canines, maxillary 4th premolars and mandibular 1st molars) are fractured or non-vital, root canal therapy is the treatment of choice in order to treat the infected tooth while allowing the pet to keep the tooth for function.

Since Bonnie had a vertical fracture of 204 that extended below the gumline and there was a significant fistulous tract present, root canal therapy was not a good option. Surgical extraction was the treatment of choice for this pet.

Clinical image of 204 postoperatively. Notice the large perforation present in this tooth (mid-tooth), which was hidden below the gumline, that would not have allowed for successful root canal therapy.



Classifications of Fractures:

1. Crown fractures—Enamel only (A): Fractures that involve only chips of enamel
Treatments: In the dog: follow radiographically every 6 months to 1 year; root canal therapy or surgical extraction is indicated if there is any sign of pulpal death. In the cat: root canal therapy or surgical extraction is recommended because most chip fractures will lead to pulp death and apical abscess formation. If on the cusp tip, restorative crown therapy may prevent further damage.

2. Crown fractures---Enamel & Dentin (B): Fractures that have entered the enamel and dentin but have not entered the pulp.

Treatments: Dogs: if enough dentin remains, indirect pulp capping & restoration with a glass ionomer, composite resin, or restorative crown therapy. If very close to the pulp, pulp capping or root canal therapy +/- restorative crown therapy is recommended.
Cats: root canal therapy is recommended.

The reason that you want to treat these teeth—is that if there is exposed dentin; bacteria can get into the pulp chamber via the dentin tubules that are exposed.

3. Crown fractures—Enamel & Dentin, exposing the pulp:

Treatment if young animal (<1.5 years of age): (C)

1. Pulp capping (vital pulpotomy) if fracture is less than 2 weeks old & patient has been on antibiotics.
2. Root canal therapy or Extraction if fracture is over 2 weeks old. If the patient is 1 year or younger, the apex of the root may not be closed and more steps may be involved before root canal therapy can be performed (dental x-rays will show if the apex is closed).

Treatment if an older animal (> 1.5 years of age): (D)

1. Pulp capping (vital pulpotomy) if the fracture has been present less than 48 hours.
2. Root canal therapy or extraction if the pulp is exposed longer than 48 hours.

4. Root Fractures: Fractures involving the roots of teeth (E)

Treatment:

1. If the fracture is in the coronal 3rd of the root, endodontic therapy followed by a post in the endodontic system (pulp chamber) of both pieces of the tooth may be attempted (prognosis is guarded though).
2. If the fracture is in the middle 3rd of the root, extraction is necessary.
3. If the fracture is in the apical 3rd of the root, a surgical root canal and extraction of the apical fragment can be performed.

5. Crown—Root Fractures: (As seen in the case above)

Fractures involving the crown and root of teeth (F)

Treatment:

1. Most of the time, extraction is the best choice. (This was the case for Bonnie)
2. Root canal therapy followed by bonding of the split root may be attempted

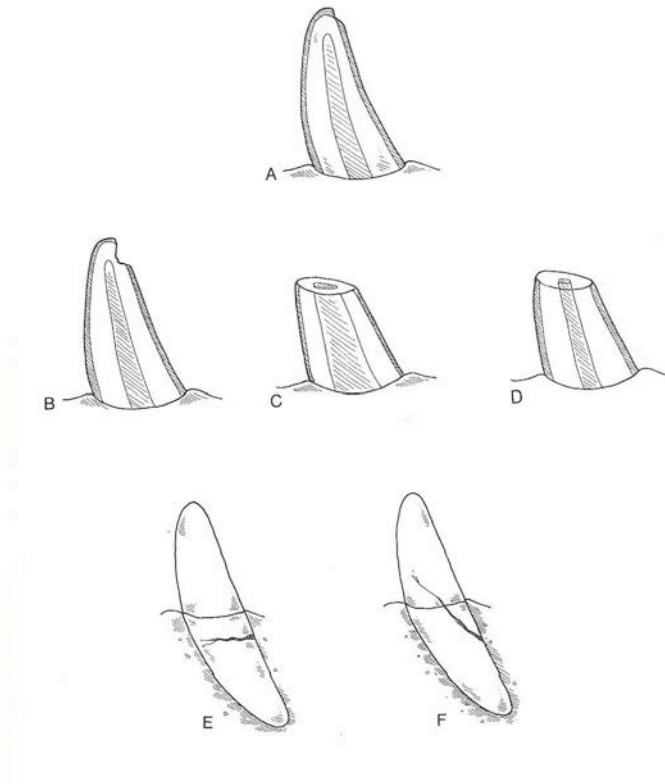


Diagram demonstrating the different fractures as listed above.

Fracture information and diagram taken from:

Holmstrom, Frost, Gammon. *Restorative dentistry*. In: Veterinary dental techniques. Philadelphia: Saunders, 1992; pg. 270-271.