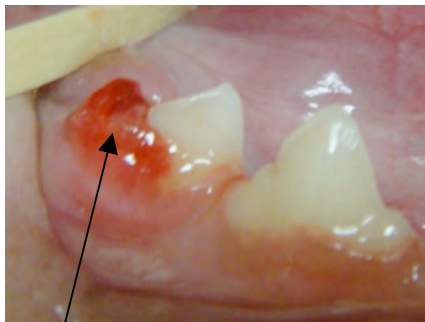


## Tooth Resorption

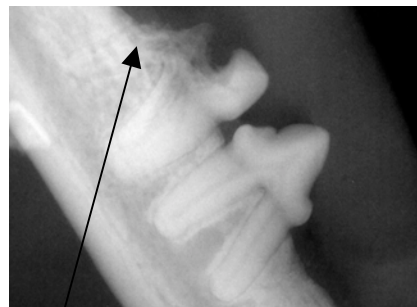


THE CAROLINAS ANIMAL HOSPITAL & DENTAL CLINIC

Tooth resorption is one of the most painful oral afflictions in cats and, less commonly, dogs. Visually, they are recognized as holes in the enamel and underlying dentin of the teeth. Despite extensive research, there is currently no concrete evidence regarding their cause. We know that they result from cells called *odontoclasts*, normally responsible for remodeling of the tooth structure. With a resorptive tooth, these cells cause the tooth structure to dissolve. Resorption progressively destroys the tooth. Once the defect extends through the enamel and into the dentin (deeper layer of the tooth), the tooth experiences sensitivity and pain. These teeth require extraction in order to eliminate this pain and continued infection. Dental x-rays are used to diagnose lesions under the gumline, to determine the extent of the lesion and to guide proper treatment. The lesions tend to occur at and just below the gumline, however it is possible for only the root structure to be affected. Approximately 60% of cats over 6 years old will have at least one lesion in their lifetime. Additionally, those that have one usually have more throughout their life. Early detection of these lesions through routine dental examinations and cleanings is essential to treat this painful condition.



Typical appearance of tooth resorption



Tooth (in photo at left) resorption on an x-ray

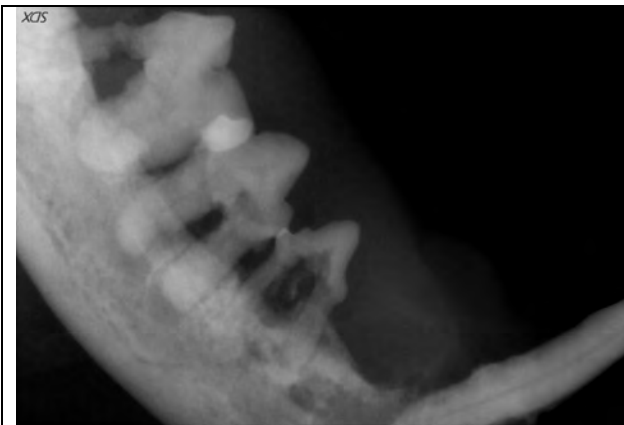
**RESORPTIVE LESIONS ARE EXTREMELY PAINFUL!!!**

**PREVENTION:**

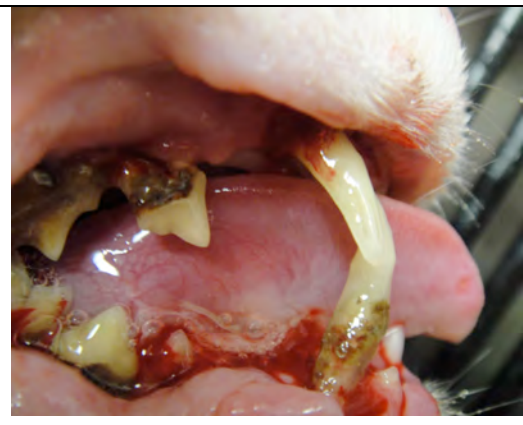Currently the cause of this feline affliction is not completely understood, therefore we can not make firm recommendations regarding prevention. Until research provides that answer, there are a few things that may help. The first is a complete dental cleaning with full mouth dental x-rays to evaluate the extent of the problem. Daily home care will reduce plaque build-up. Fluoride is a controversial treatment because, while application may make your cat's teeth less susceptible to this disease, it is toxic if swallowed so it is difficult to effectively use it for home-care.

**DENTAL PAIN:**

Interestingly, many owners of cats with resorptive disease do not think their pet appears to be in pain. However, from an evolutionary standpoint, this is not surprising. If in the wild a cat displayed this illness or distress, they would likely become prey. Also, if dental pain caused them to stop eating, they would soon become so weak they would starve or be unable to hunt. Therefore, they are typically stoic and carry on in pain. After treatment of dental disease and extraction of painful teeth is performed, the improvement in their attitude and demeanor is oftentimes dramatic.



Dental x-ray of tooth resorption



Severe resorptive disease (cat)